

Vibration-induced ocular torsion and nystagmus after unilateral vestibular deafferentation

Mikael Karlberg,^{1,3} Swee T. Aw,¹ Ross A. Black,¹ Michael J. Todd,¹ Hamish G. MacDougall² and G. Michael Halmagyi¹

¹Neuro-otology Department, Royal Prince Alfred Hospital, ²Department of Psychology, University of Sydney, Sydney, Australia and ³Department of Oto-rhino-laryngology, Head and Neck Surgery, Lund University Hospital, Lund, Sweden

Correspondence to: Dr Mikael Karlberg, Department of Oto-rhino-laryngology, Head and Neck Surgery, Lund University Hospital, SE-221 85 Lund, Sweden
E-mail: mikael.karlberg@onh.lu.se

Summary

Vibration is an excitatory stimulus for both vestibular and proprioceptive afferents. Vibration applied either to the skull or to the neck muscles of subjects after unilateral vestibular deafferentation induces nystagmus and a shift of the subjective visual horizontal. Previous studies have ascribed these effects to vibratory stimulation of neck muscle proprioceptors. Using scleral search coils, we recorded three-dimensional eye movements during unilateral 92 Hz vibration of the mastoid bone or of the sternocleidomastoid (SCM) muscle in 18 subjects with chronic unilateral vestibular deficits after vestibular neurectomy or neuro-labyrinthitis. Nine subjects had lost function of all three semicircular canals (SSCs) on one side, and the other nine had lost function of only the anterior and lateral SSCs. Vibration of the mastoid bone or of the SCM muscle on either side induced an ipsilesional tonic shift of torsional eye position of up to 6.5° during visual fixation, as well as a nystagmus with horizontal, vertical and torsional components in darkness. Subjects who had lost function of all three SSCs on one side showed a larger shift in ocular torsion in

response to SCM vibration than did subjects who had lost function of only two SSCs. The difference between ocular torsion produced by ipsilesional muscle or bone vibration was not significantly different from that produced by contralesional bone or muscle vibration. The vibration-induced nystagmus rotation axis tended to align with the pitch (y) axis of the head in subjects who had lost only anterior and lateral SSC function, and with the roll (x) axis of the head in subjects who had lost function of all three SSCs. We propose that the previously described vibration-induced shift of the subjective visual horizontal can be explained by the vibration-induced ocular torsion, and that the magnitude of ocular torsion is related to the extent of the unilateral vestibular deficit. While altered proprioceptive inputs from neck muscles might be important in the mechanism of vibration-induced ocular torsion and nystagmus after unilateral vestibular deafferentation, vibratory stimulation of vestibular receptors in the intact labyrinth also appears to have an important role.

Keywords: cervico-ocular reflex; eye movements; labyrinth; proprioception; vertigo

Abbreviations: CI = confidence interval; r.m.s. = root mean square; SCC = semicircular canal; SCM = sternocleidomastoid; uVD = unilateral vestibular deafferentation

Introduction

Vibration is an excitatory stimulus not only for cochlear afferents (Robles and Ruggero, 2001) but also for semicircular canal (SCC) and otolith afferents (Young *et al.*, 1977; Wit *et al.*, 1984; Hudspeth, 1989; Christensen-Dalsgaard and Narins, 1993). Vibration applied to the mastoid bone induces nystagmus in ~80% of subjects with chronic unilateral peripheral vestibular lesions (Hamann and Schuster, 1999). Recently we reported that vibration applied to the mastoid bones of subjects with chronic unilateral vestibular deafferentation (uVD) induces a tonic shift of the subjective

visual horizontal (Karlberg *et al.*, 2002), similar to that seen acutely after uVD, in the absence of vibration (Curthoys *et al.*, 1991). Stimulation of intact vestibular receptors might explain both vibration-induced nystagmus and the shift of the subjective visual horizontal in uVD subjects.

Vibration, however, also excites proprioceptors and especially primary muscle spindle afferents (Burke *et al.*, 1976; Roll *et al.*, 1989). For example, vibration applied to a muscle can induce changes in apparent body orientation and sensory localization: vibratory myaesthetic illusions (Lackner and

Levine, 1979; Biguer *et al.*, 1988; Strupp *et al.*, 1998). Vibration applied to the dorsal neck muscles of subjects with unilateral vestibular lesions induces nystagmus with horizontal, vertical and torsional components (Yagi and Ohyama, 1996). Vibration applied to the sternocleidomastoid (SCM) muscles of chronic uVD subjects induces a tonic shift of the subjective visual horizontal (Betts *et al.*, 2000; Karlberg *et al.*, 2002). Thus, vibration applied either to the skull or to the neck muscles induces similar oculo-motor and perceptual effects after uVD. Most previous studies have ascribed these effects to vibratory stimulation of neck proprioceptors (Biguer *et al.*, 1988; Yagi and Ohyama, 1996; Strupp *et al.*, 1998; Popov *et al.*, 1999; Betts *et al.*, 2000).

The first aim of the present study was to assess whether vibration to the SCM muscle or the mastoid bone of uVD subjects changes tonic torsional eye position, as this might explain the previously reported vibration-induced shift of the subjective visual horizontal (Betts *et al.*, 2000; Karlberg *et al.*, 2002). As all subjects also had a vestibular head impulse test (Halmagyi and Curthoys, 1988; Aw *et al.*, 1996), we knew the function or lack of function of the six SCCs (Cremer *et al.*, 1998; Aw *et al.* 2001). Thus, the second aim of the study was to assess if the rotation axes of vibration-induced nystagmus differed between subjects with unilateral loss of two SCCs and those with loss of all three SCCs, which could indicate that the nystagmus is induced by vibratory stimulation of intact SCC receptors. Furthermore, we also wanted to compare vibration-induced nystagmus with head-shaking nystagmus, a well-known sign of uVD (Hain *et al.*, 1987).

Subjects and methods

Subjects

We studied 18 subjects (12 men and six women, mean age 51 years, range 25–73 years) with chronic uVD. They were recruited from among patients in the clinical database at the Department of Neuro-otology, and had participated in previous studies (Aw *et al.*, 2001; Karlberg *et al.*, 2002). All subjects were studied with the head impulse test in the planes of the three pairs of SCCs, to reveal the function of the six individual SCCs (Aw *et al.*, 1996, 2001; Cremer *et al.*, 1998). Seven subjects, six with vestibular schwannoma and one with Ménière's disease, had undergone unilateral vestibular neurectomy. They had unilateral loss of function of all three SCCs. Eleven subjects had permanent unilateral peripheral loss of vestibular function following vestibular neuro-labyrinthitis. Of these 11 subjects, two had lost function in all three SCCs, and nine had lost function of only the anterior and lateral SCCs ('superior vestibular neuritis') (Fetter and Dichgans, 1996; Aw *et al.*, 2001). The average time since the uVD was 32 months, range 1–144 months. Thirteen of the 18 subjects had horizontal spontaneous nystagmus in darkness (magnetic search coil recordings) with a maximal slow phase velocity of 1.1°/s. Seven of the 18 subjects still had a pathological subjective

visual horizontal test result ($>3^\circ$) without vibration. Two of these seven patients had spontaneous horizontal nystagmus in darkness. All subjects gave their written informed consent after being briefed about the examination. The Royal Prince Alfred Hospital Human Ethics Committee had approved the experimental procedures. All experiments were performed in accordance with the Declaration of Helsinki.

The vibratory stimulus

We used a hand-held battery-powered vibrator (Mini Vibrator NC70209, North Coast Medical, Inc., San Jose, CA, USA). The semi-spherical vibrating silicon tip had a radius of 8 mm, and vibrated at 92 Hz with 0.6 mm amplitude. In order to decide how best to perform neck muscle vibration, we made a preliminary investigation in four uVD subjects. We applied unilateral vibration to the posterior neck, probably vibrating the splenius muscle, as well as to the SCM muscle. We adjusted the position of the vibrator as in previous studies until the subjects indicated a perceived sensation of movement of a visually fixated laser dot (Biguer *et al.*, 1988; Strupp *et al.*, 1998; Popov *et al.*, 1999). Eye movements were recorded as described below. Unilateral posterior neck vibration and SCM muscle vibration induced similar eye movements, but the responses were larger and more reproducible during SCM muscle vibration. Thus, SCM muscle vibration was chosen, and the positioning of the vibrator and the vibration procedures were the same as in our previous study on vibration-induced shift of the subjective visual horizontal (Karlberg *et al.*, 2002).

For vibrations applied to the SCM muscle, the mastoid process and the belly of the SCM muscle were palpated during static muscle contraction, and a point over the muscle belly, 25 mm below the tip of the mastoid process, was marked with a pen. The vibrator was positioned on the marked spot, perpendicular to the skin, and held in position by hand. During mastoid bone vibration, the tip of the vibrator was positioned perpendicular to the skin overlying the mastoid, level with the external ear canal and held in position by hand. The same examiner (M.K.) delivered the vibrations to all subjects.

Quantification of the applied vibrations

We tried to measure the vibration of the head during mastoid bone and SCM muscle vibration in three healthy male subjects. The subjects were seated upright with the head restrained in a head-holder. The subjects held an tri-axial accelerometer (ADXL 150EM-3, Analog Devices, Norwood, MA, USA) between their teeth. The device was calibrated to 1 G along three axes. The signal was amplified, recorded by computer and analysed off-line. The vibrator was applied to the right mastoid or to the right SCM muscle as described above. The acceleration of the head was measured in approximately the interaural, naso-occipital and cranio-caudal axes as the root mean square (r.m.s.) of the

accelerometer signal during the period of vibration relative to 1 *g* (where *g* is the acceleration of gravity). The r.m.s. values of the three measured axes were summed to represent total skull acceleration.

During unilateral mastoid bone vibration, the sum of r.m.s. of head acceleration for the three subjects was 0.06, 0.09 and 0.1 *g* (mean 0.08). During unilateral SCM muscle vibration, it was 0.07, 0.04 and 0.06 *g* (mean 0.06). These values are between -10 and -15 dB relative to 1 *g*, and are well over the threshold for vibratory sensitivity in squirrel monkey SCC afferents (-25 dB relative to 1 *g* at 80 Hz) (Young *et al.*, 1977).

Experimental protocol

We used the scleral search coil technique to record the torsional, vertical and horizontal position of the left eye and the head (Robinson, 1963). Detailed descriptions of the equipment and the calibration and recording procedures have been presented elsewhere (Aw *et al.*, 1996). First, head-shaking nystagmus (Hain *et al.*, 1987) was recorded in complete darkness. The head of the subject was shaken passively in the horizontal plane by an examiner (M.K.), who stood behind the patient. The head was shaken 25 times at ~2 Hz and then abruptly kept still in mid-position. The subject was instructed to keep the eyes open and to look straight ahead. Eye movement recordings were conducted during and for 60 s after head shaking. Next, vibration-induced eye movements were recorded. The subject's head was immobilized in a head-chin holder, which was adjusted individually to fit each subject. First a baseline recording without vibration was made. Then recordings were made during vibration to the left and right SCM muscle, and the left and right mastoid bone. The same test order was used for all subjects. Initially, the subject was asked to stare at a laser fixation target that was back-projected onto a screen at a distance of 94 cm directly in front. Five seconds after the start of recording, vibration was applied for a 10 s period, stopped for 10 s and then started again. After 25 s of recording, the laser fixation target was extinguished and the subject was instructed to continue to look straight ahead while the vibration continued for another 30 s (Fig. 1). The eye position recordings were analysed off-line in three dimensions as rotation vectors and then converted to degrees. We measured the amplitude of vibration-induced static torsion during visual fixation and slow phase velocities of vibration-induced horizontal, vertical and torsional nystagmus in darkness.

Statistical analysis

To enable the recordings from all subjects to be used for statistical analysis, individual data of eye position were pooled as if all subjects had left-sided uVD. Statistical analysis was performed with ANOVA (analysis of variance) and *post hoc* tests according to Bonferroni, and with the

Student's *t* test for unpaired observations. A difference where $P < 0.05$ was considered statistically significant.

Results

Vibration-induced ocular torsion

Vibration of either the mastoid bone or of the SCM muscle on either side, in all subjects, induced a tonic shift of torsional eye position during visual fixation, with the upper pole of the eye always rotating toward the lesioned side (Fig. 1). There were no significant changes of torsional head position. The maximal ocular torsion during mastoid bone vibration was 6.2° [mean 3.5°, 95% confidence interval (CI) 2.9–4.0°] and that during SCM muscle vibration was 6.9° (mean 3.1°, 95% CI 2.7–3.6°). There were no significant differences between: (i) the ocular torsion induced by mastoid bone vibration and that induced by SCM muscle vibration on either side ($P = 0.15$, ANOVA) (Table 1); (ii) the ocular torsion induced by ipsilesional and that induced by contralesional vibration ($P = 0.15$, ANOVA) (Table 1); and (iii) the ocular torsion induced by mastoid bone vibration in subjects with loss of three SCCs and those with loss of two SCCs (Table 2). However, the ocular torsion induced by SCM muscle vibration, on either side, was significantly larger in subjects with loss of three SCCs than in those with loss of only two SCCs (Table 2).

Vibration-induced nystagmus and head-shaking nystagmus

In darkness, vibration to the mastoid bone or to the SCM muscle on either side induced nystagmus or significantly increased any spontaneous nystagmus in 14 of the 18 tested subjects. Passive head shaking also induced nystagmus in 10 of the 14 subjects with vibration-induced nystagmus (Fig. 1, Table 3). The horizontal slow phase component of the vibration-induced nystagmus and of the head-shaking nystagmus was always directed to the side of the lesion (i.e. it was 'ipsilesional'). There were no significant differences between the slow phase velocity of the nystagmus induced by mastoid vibration and that induced by SCM muscle vibration on either side ($n = 14$, horizontal component, $P = 0.93$; vertical component, $P = 0.26$; torsional component, $P = 0.51$, ANOVA), or between the vibration-induced nystagmus and the head-shaking nystagmus ($n = 10$, horizontal component, $P = 0.36$; vertical component, $P = 0.74$; torsional component, $P = 0.88$, ANOVA) (Table 2).

The mean rotation axes of both vibration-induced nystagmus and head-shaking nystagmus tended to align with an axis orthogonal to the plane of the intact lateral SCC (Fig. 2). The rotation axes of vibration-induced nystagmus in subjects with loss of two SCCs tilted significantly more from the yaw (*z*) axis towards the pitch (*y*) axis than did that of subjects with loss of three SCCs. In contrast, the rotation axis of vibration-induced nystagmus of the subjects with loss of three SCCs

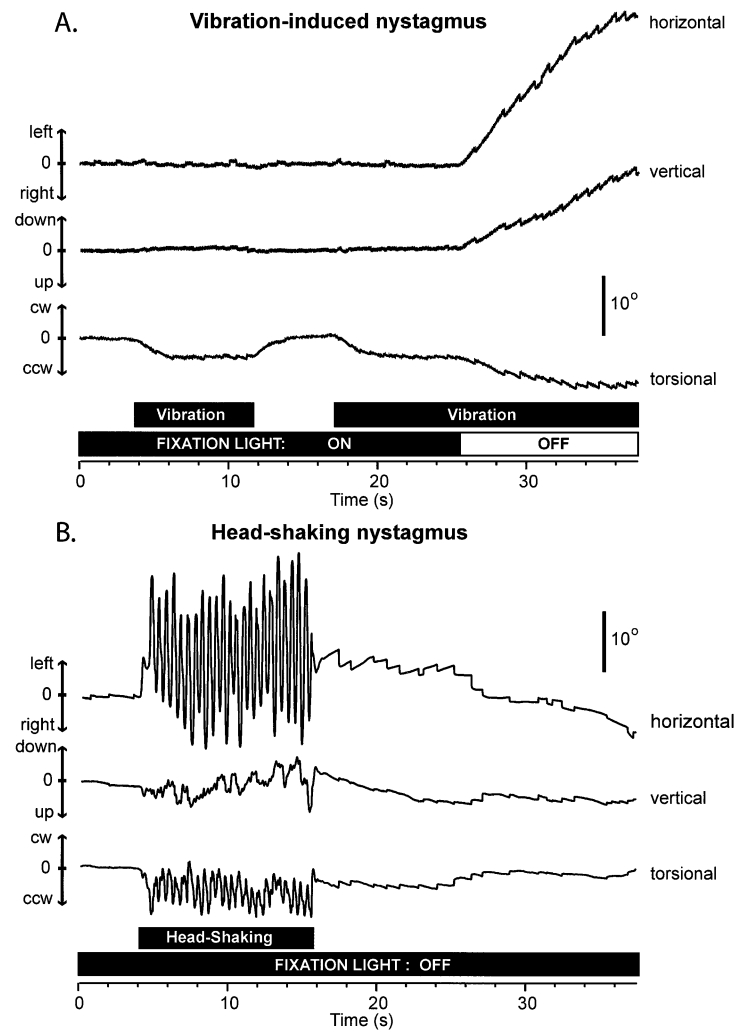


Fig. 1 Position recordings of the left eye of a subject with left-sided uVD after surgery for a vestibular schwannoma. Eye position is plotted according to the right-hand rule, with eye movements to the left, down and clockwise, as seen from the subject's view, as positive. (A) The subject initially fixates on a laser dot. During vibration to the left SCM muscle, the upper pole of the eye rotates toward the left shoulder and there is an $\sim 5^\circ$ tonic torsional position shift. There are no tonic shifts of horizontal or vertical eye position. When the fixation light is extinguished, a nystagmus with horizontal, vertical and torsional components appears, and the eye deviates tonically in the slow phase directions of the nystagmus. (B) After passive horizontal head shaking, there is a decaying right-beating horizontal nystagmus with small torsional and vertical components. Note that the vertical components of the two recordings are in opposite directions.

tilted significantly more from the yaw (z) axis rotation towards the roll (x) axis, than did that of subjects with loss of two SCCs. The rotation axes of head-shaking nystagmus did not differ between subjects with loss of two and three SCCs (Fig. 2).

Discussion

We have found that in chronic compensated uVD subjects, both mastoid bone and SCM muscle vibration, to either side, will induce tonic ocular torsion in the light, and an additional nystagmus with horizontal, vertical and torsional components in the dark. The tonic ocular torsion and the horizontal and

torsional slow phase components of the nystagmus are always ipsilesional. In other words, in chronic uVD subjects, vibration to the skull or to the neck evokes eye movements that are similar to those seen, temporarily, even without vibration, acutely after uVD.

We have also found that in subjects with chronic uVD, the direction and average magnitude of the vibration-induced ocular torsion correspond to those of vibration-induced shift of the subjective visual horizontal (Betts *et al.*, 2000; Karlberg *et al.*, 2002). The present results therefore suggest that the vibration-induced shift of the subjective visual horizontal is secondary to a vibration-induced shift in ocular

torsion, as is the case spontaneously in the acute stage of uVD (Curthoys *et al.*, 1991). Subjects with unilateral loss of three SCCs show significantly larger ocular torsion during SCM muscle vibration on either side than do subjects with loss of only two SCCs. As all subjects had lost lateral SCC function, the magnitude of the vibration-induced ocular torsion should not reflect the deficit of the lateral SCC function but instead might reflect the deficit of vertical SCC function or otolith function, or both.

Could the ocular torsion we found have been due to head tilt induced by the applied pressure of the vibrator? We think not, since we did not record any significant head movements during vibration. Furthermore, if the ocular torsion was secondary to head tilt, one would expect the direction of ocular torsion to be dependent on which side was vibrated, and we did not find this: ocular torsion was always directed towards the side of the vestibular lesion.

It could be said that the ideal way to study the relationship between ocular torsion and subjective visual horizontal would be to measure eye position and subjective visual horizontal simultaneously, in this case during vibration. However, this experiment not only is technically daunting, but the results

could also be hard to interpret, since rotation of the light bar used to measure the subjective visual horizontal itself induces ocular torsion (Curthoys *et al.*, 2002).

It should be noted that vibration either to the SCM muscle (Betts *et al.*, 2000; Karlberg *et al.*, 2002) or to the dorsal neck (Strupp *et al.*, 1998) produces significantly larger perceptual effects when applied ipsilesionally than when applied contralesionally. We found no significant difference between the ocular torsion induced by vibration to the mastoids or the SCM muscles on each side. One possible explanation of this discrepancy is that it might take longer than the 10 s of vibration we used here to induce maximal ocular torsion. In the subjective visual horizontal studies, vibration was applied for as long as it took for the subject to making repeated settings of the subjective visual horizontal, typically from 1 to 2 min (Karlberg *et al.*, 2002). One reason why we used only 10 s of vibration here was in order to reduce the chance of torsional coil slip, especially during blinks.

It has been suggested that horizontal head-shaking nystagmus in chronic uVD subjects is due to the combined operation of Ewald's second law and central velocity storage (Hain *et al.*, 1987). During each cycle of head rotation, there is a net predominance of ipsilesional slow phases that gradually accumulate in the velocity storage mechanism. When the head shaking stops, the discharge of the velocity storage leads to nystagmus (Hain *et al.*, 1987). We found that the rotation axis of head-shaking nystagmus was the same in the subjects with loss of either two or three SCCs. This is not surprising, as all subjects had lost function of the lateral SCC, and horizontal head shaking will activate the lateral SCC preferentially. However, the eye rotation axis of vibration-induced nystagmus differed significantly between the two groups of subjects (Fig. 2), which suggests that the mechan-

Table 1 *Vibration-induced tonic ocular torsion in uVD patients (n = 18)*

	Mastoid bone vibration	SCM muscle vibration
Vibration to intact side	4.0° (3.2–4.8°)	3.0° (2.4–3.6°)
Vibration to lesioned side	3.0° (2.2–3.7°)	3.3° (2.6–4.0°)

Mean (95% CI).

Table 2 *Vibration-induced tonic ocular torsion in uVD patients with loss of two or three SCCs*

	Three SCC loss (n = 9)	Two SCC loss (n = 9)	
SCM muscle vibration intact side	3.7° (3.0–4.3°)	2.2° (1.5–2.9°)	<i>P</i> < 0.01
SCM muscle vibration lesioned side	3.9° (2.9–4.9°)	2.6° (1.9–3.3°)	<i>P</i> < 0.05
Mastoid bone vibration intact side	4.0° (3.3–4.8°)	3.9° (2.5–5.4°)	<i>P</i> = 0.89
Mastoid bone vibration lesioned side	3.3° (2.2–4.4°)	2.6° (1.6–3.5°)	<i>P</i> = 0.36

Mean (95% CI) and significance level for two-tailed unpaired Student's *t* test.

Table 3 *Slow phase velocities of the horizontal, vertical and torsional components of vibration-induced and head-shaking nystagmus in 14 chronic uVD subjects (n = 10 for head-shaking nystagmus)*

	Horizontal	Vertical	Torsional
Baseline (no vibration)	0.5 (0.2–0.7°/s)	0.3 (0.0–0.6°/s)	0.2 (0.1–0.3°/s)
SCM muscle intact side	3.0 (1.6–4.5°/s) <i>P</i> < 0.05	0.7 (0.4–1.0°/s) <i>P</i> = 1.00	1.1 (0.7–1.6°/s) <i>P</i> = 0.07
SCM muscle lesioned side	3.4 (2.0–4.8°/s) <i>P</i> < 0.01	1.2 (0.6–1.7°/s) <i>P</i> = 0.24	1.5 (1.0–2.0°/s) <i>P</i> < 0.01
Mastoid bone intact side	3.1 (2.4–3.7°/s) <i>P</i> < 0.05	1.4 (0.8–2.1°/s) <i>P</i> < 0.01	1.5 (1.1–1.9°/s) <i>P</i> < 0.001
Mastoid bone lesioned side	3.6 (2.0–5.3°/s) <i>P</i> < 0.01	0.7 (0.3–1.2°/s) <i>P</i> = 1.00	1.3 (0.7–1.9°/s) <i>P</i> < 0.01
Head-shaking nystagmus	4.9 (3.4–6.4°/s) <i>P</i> < 0.001	0.9 (0.3–1.4°/s) <i>P</i> = 1.00	1.4 (0.8–2.0°/s) <i>P</i> = 0.11

Mean (95% CI) and significance level for ANOVA with *post hoc* tests according to Bonferroni, as compared with baseline values.

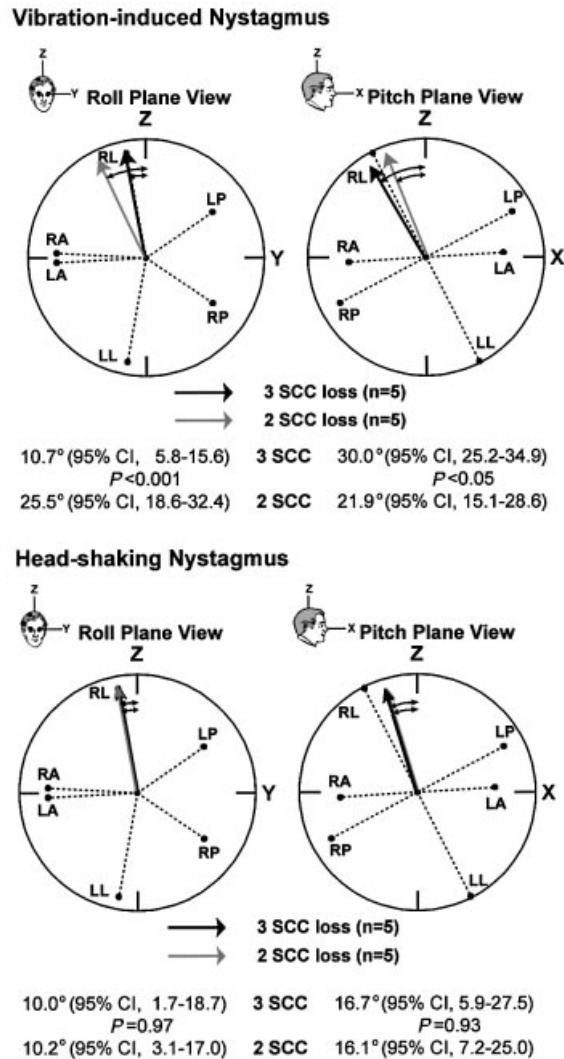


Fig. 2 Mean slow phase velocity eye rotation axes of vibration-induced and head-shaking nystagmus in subjects with unilateral loss of three or two SCCs. The eye rotation axes of vibration-induced nystagmus of subjects with loss of three SCCs tilted more toward the roll (x) axis ($P < 0.05$, Student's t test), while those of subjects with loss of two SCCs tilted more toward the pitch (y) axis ($P < 0.001$, Student's t test). The eye rotation axes of head-shaking nystagmus did not differ between the two groups of subjects. RL = right lateral; RA = right anterior; RP = right posterior; LL = left lateral; LA = left anterior; and LP = left posterior SCC plane vector.

ism that produces vibration-induced nystagmus is different from that which produces head-shaking nystagmus.

The possible role of neck proprioceptors in vibration-induced torsion and nystagmus

It has been proposed that the direction of vibratory myaesthetic illusions depends on the natural action of the vibrated muscle (Lackner and Levine, 1979). The neck vibration of previous studies was 'standardized' by adjusting

the position of the vibrator until the subject perceived an illusion of movement of a stationary visual target (Biguer *et al.*, 1988; Strupp *et al.*, 1998; Popov *et al.*, 1999). This position dependency has been used as an argument against vibratory stimulation of vestibular receptors (Biguer *et al.*, 1988). In our preliminary investigation, we applied vibration to the posterior neck and to the SCM muscle, and compared the vibration-induced eye movements. Vibration to the posterior neck probably vibrates the splenius muscle, which rotates and extends the neck (Mayoux-Benhamou *et al.*, 1997), whereas the SCM muscle rotates, flexes and lateroflexes the neck (Conley *et al.*, 1995). We adjusted the position of the vibrator as in the previous studies. Unilateral vibration to the posterior neck or to the SCM muscles on either side induced the same eye movements, i.e. tonic ocular torsion during visual fixation and nystagmus in darkness. Thus, it seems as if the oculomotor response to neck vibration of chronic uVD subjects differs from the response of normal subjects in being stereotypical and not dependent on the natural action of the vibrated muscle. Furthermore, as we have shown here, mastoid bone vibration and SCM muscle vibration evoke similar eye movements. It is possible that vibration applied to the SCM muscle belly adjacent to the mastoid bone activated the vestibular receptors and that this can account for the similarity of oculomotor responses to vibration of SCM muscle and mastoid bone.

Tonic horizontal eye position shifts during dorsal neck vibration have been reported in patients studied weeks to months after acute vestibular neuritis and also in normal subjects. Normals showed eye deviations of up to 6° toward the vibrated side, while the vestibular neuritis patients showed eye deviations of up to 25° when the ipsilesional neck was vibrated. These eye position shifts were reported to occur even though the subjects tried to fixate on a laser dot in front of them (Strupp *et al.*, 1998). None of our patients showed horizontal eye deviations in response to vibration during visual fixation. However, when the fixation light was extinguished, the eye deviated in the direction of the slow phase of the induced nystagmus (Fig. 1). Horizontal eye deviation in the direction of the slow phase of spontaneous nystagmus is found in darkness during the acute stage of uVD (Hörnsten, 1979).

The possible role of vestibular receptors in vibration-induced torsion and nystagmus

If the hair bundle of a vestibular hair cell is deflected mechanically, the cell exhibits a sigmoidal response curve (Hudspeth, 1989). Most cells show saturation in the negative stimulus direction but no abrupt or complete saturation for positive stimuli (Hudspeth, 1989). Thus, movements of the hair bundle toward the kinocilium will depolarize the cell more than movements of the same amplitude in the opposite direction will hyperpolarize it. The net effect of an oscillating

mechanical stimulus to a hair bundle will be excitatory (Hudspeth, 1989).

Vibrations of different frequencies have been shown to excite saccular afferents in frogs (Christensen-Dalsgaard and Narins, 1993), lateral SCC afferents in pigeons (Wit *et al.*, 1984) and both SCC and otolith afferents in squirrel monkeys (Young *et al.*, 1977). Our measurement of head acceleration during SCM muscle vibration showed that head acceleration was about three-quarters of that observed during mastoid bone vibration. It should be noted that the absolute value of head acceleration, however, was ~10 times the vibratory threshold for squirrel monkey SCC afferents (Young *et al.*, 1977).

The most compelling argument for vibratory stimulation of vestibular receptors arises from work which shows that stimulation of the receptors of the vertical SCCs induces torsional eye movements (Suzuki *et al.*, 1964; Cremer *et al.*, 2000). Stimulation of neck muscle spindles has not, to our knowledge, been reported to cause torsional eye movements.

The observation that the mean rotation axis of vibration-induced nystagmus in subjects with loss of two SCCs tilted towards the pitch (*y*) axis, whereas the mean rotation axis in subjects with loss of three SCCs tilted toward the roll (*z*) axis, is yet another argument in favour of intact vestibular excitation being responsible for vibration-induced torsion and nystagmus. This observation indicates that vibration-induced nystagmus reflects the function of the remaining intact SCCs. In three SCC loss subjects, the torsional components of the nystagmus induced by stimulation of the anterior and posterior SCCs on the intact side will be additive, but the vertical components of the nystagmus will cancel each other out. In contrast, in subjects with loss of two SCCs, stimulation of the one unopposed vertical canal on the intact side will result in less torsional and more vertical nystagmus components. The function of the saccule, which is innervated by the inferior vestibular nerve, is usually spared in patients with superior vestibular neuritis (Murofushi *et al.*, 1996). Thus, the saccule might also play a role in the vertical nystagmus of the patients with loss of two SCCs; however, sacculo-ocular connections have been shown to be scarce in cats (Isu *et al.*, 2000), and it is not known whether there is a sacculo-ocular reflex in man.

The rotation vectors of vibration-induced nystagmus tended to aggregate around the intact lateral SCC and not around the calculated summed response of the intact SCCs. This anisotropy of oculomotor response to vestibular stimulation has also been reported for spontaneous nystagmus after acute uVD. A possible explanation for this anisotropy is the difference in gain and central velocity storage between the lateral and vertical SCCs (Bohmer *et al.*, 1997). Vibration preferentially excites the same irregularly firing vestibular neurons that are sensitive to galvanic vestibular stimulation (Young *et al.*, 1977) and mediate the vestibulo-ocular reflex via indirect pathways through the velocity storage mechanism (Angelaki *et al.*, 1992; Karlberg *et al.*, 2000).

Eye movements induced by dorsal neck vibration have been studied previously in normal subjects and patients with

chronic bilateral vestibular loss (Popov *et al.*, 1999). These patients showed nystagmus-like vertical-torsional eye movements in response to vibration, whereas normal subjects showed predominantly horizontal eye movements with lower velocities and smaller magnitudes. The vertical-torsional eye movements induced by dorsal neck vibration in the patients with absent vestibular function were explained by compensatory enhancement of the vertical cervico-ocular reflex, presumably related to vertical oscillopsia. However, as the diagnosis of bilateral vestibular loss in these patients was based only on caloric and rotary chair tests, which only measure lateral SCC function, an alternative explanation of these results is vibratory stimulation of intact vertical SCC afferents (Suzuki *et al.*, 1964; Cremer *et al.*, 2000).

Recent studies concerning the mechanisms of auditory bone conduction might explain why mastoid bone and SCM muscle vibration in chronic uVD subjects induce similar oculomotor responses. Vibration applied directly to the intracranial contents elicits auditory brainstem-evoked responses at the same thresholds as vibration applied to the bones of the skull (Freeman *et al.*, 2000; Sohmer *et al.*, 2000). This has been shown on exposed rat brain at craniotomy. Extensive removal of skull bone did not alter the response, but reduction of CSF elevated the response threshold (Freeman *et al.*, 2000). Vibration over the fontanels in human babies, to the skin overlying craniotomies in patients after neurosurgery or to the eye-ball in healthy subjects produced auditory brainstem-evoked responses at similar thresholds, as did stimulation with a bone conductor to different sites on the head (Sohmer *et al.*, 2000). It has been suggested that vibration applied to the skull or directly to the intracranial contents, and thus presumably also to the upper neck, induces pressure waves in the brain and CSF. The pressure waves are then communicated via the cochlear and vestibular aqueducts and internal auditory meatus to the inner ear fluids where they excite the auditory receptors (Freeman *et al.*, 2000; Sohmer *et al.*, 2000). The same mechanism might also mediate vibratory excitation of the vestibular receptors.

In summary, vibration to the mastoid bone or SCM muscle of chronic uVD subjects induces eye movements similar to those seen temporarily, without vibration, acutely after uVD. We propose that the previously described vibration-induced shift of the subjective visual horizontal can be explained by the vibration-induced ocular torsion, the magnitude of which is related to the extent of unilateral vertical SCC deficit or otolithic deficit, or both. Whereas altered proprioceptive inputs from neck muscles might be important in the mechanism of vibration-induced eye movements after uVD, the results of the present study suggest that vibratory stimulation of intact vestibular receptors is even more important.

Acknowledgements

This study was supported by the National Health and Medical Research Council of Australia, Canberra, the Garnett Passe

and Rodney Williams Memorial Foundation, Melbourne, and the trustees of the Department of Neurology of the Royal Prince Alfred Hospital, Sydney, Australia. M.K. was supported by grants from the Swedish Medical Research Council, Stockholm, the Wenner-Gren Foundations, Stockholm, the Swedish Medical Association, Stockholm, and the Maggie Stephens Foundation, Lund, Sweden.

References

- Angelaki DE, Perachio AA, Mustari MJ, Strunk CL. Role of irregular otolith afferents in the steady-state nystagmus during off-vertical axis rotation. *J Neurophysiol* 1992; 68: 1895–900.
- Aw ST, Halmagyi GM, Haslwanter T, Curthoys IS, Yavor RA, Todd MJ. Three-dimensional vector analysis of the human vestibuloocular reflex in response to high-acceleration head rotations. II. Responses in subjects with unilateral vestibular loss and selective semicircular canal occlusion. *J Neurophysiol* 1996; 76: 4021–30.
- Aw ST, Fetter M, Cremer PD, Karlberg M, Halmagyi GM. Individual semicircular canal function in superior and inferior vestibular neuritis. *Neurology* 2001; 57: 768–74.
- Betts GA, Barone M, Karlberg M, MacDougall H, Curthoys IS. Neck muscle vibration alters visually-perceived roll after unilateral vestibular loss. *Neuroreport* 2000; 11: 2659–62.
- Biguer B, Donaldson IM, Hein A, Jeannerod M. Neck muscle vibration modifies the representation of visual motion and direction in man. *Brain* 1988; 111: 1405–24.
- Bohmer A, Straumann D, Fetter M. Three-dimensional analysis of spontaneous nystagmus in peripheral vestibular lesions. *Ann Otol Rhinol Laryngol* 1997; 106: 61–8.
- Burke D, Hagbarth KE, Lofstedt L, Wallin BG. The responses of human muscle spindle endings to vibration of non-contracting muscles. *J Physiol* 1976; 261: 673–93.
- Christensen-Dalsgaard J, Narins PM. Sound and vibration sensitivity of VIIIth nerve fibers in the frogs *Leptodactylus albilabris* and *Rana pipiens pipiens*. *J Comp Physiol* 1993; 172: 653–62.
- Conley MS, Meyer RA, Bloomberg JJ, Feedback DL, Dudley GA. Noninvasive analysis of human neck muscle function. *Spine* 1995; 20: 2505–12.
- Cremer PD, Halmagyi GM, Aw ST, Curthoys IS, McGarvie LA, Todd MJ, et al. Semicircular canal plane head impulses detect absent function of individual semicircular canals. *Brain* 1998; 121: 699–716.
- Cremer PD, Minor LB, Carey JP, Della Santina CC. Eye movements in patients with superior canal dehiscence syndrome align with the abnormal canal. *Neurology* 2000; 55: 1833–41.
- Curthoys IS, Dai MJ, Halmagyi GM. Human ocular torsional position before and after unilateral vestibular neurectomy. *Exp Brain Res* 1991; 85: 218–25.
- Curthoys IS, Mezey LE, Burgess AM, Macdougall HG. Changes in ocular torsional position produced by a single moving visual line—visual ‘entrainment’. *J Vestib Res* 2002; 11: 307–8.
- Fetter M, Dichgans J. Vestibular neuritis spares the inferior division of the vestibular nerve. *Brain* 1996; 119: 755–63.
- Freeman S, Sichel JY, Sohmer H. Bone conduction experiments in animals—evidence for a non-osseous mechanism. *Hear Res* 2000; 146: 72–80.
- Hain TC, Fetter M, Zee DS. Head-shaking nystagmus in patients with unilateral peripheral vestibular lesions. *Am J Otolaryngol* 1987; 8: 36–47.
- Halmagyi GM, Curthoys IS. A clinical sign of canal paresis. *Arch Neurol* 1988; 45: 737–9.
- Hamann KF, Schuster EM. Vibration-induced nystagmus—a sign of unilateral vestibular deficit. *ORL J Otorhinolaryngol Relat Spec* 1999; 61: 74–9.
- Hörnsten G. Constant error of visual egocentric orientation in patients with acute vestibular disorder. *Brain* 1979; 102: 685–700.
- Hudspeth AJ. Mechano-electrical transduction by hair cells of the bullfrog’s sacculus. *Prog Brain Res* 1989; 80: 129–35.
- Isu N, Graf W, Sato H, Kushiro K, Zakir M, Imagawa M, Uchino Y. Sacculo-ocular reflex connectivity in cats. *Exp Brain Res* 2000; 131: 262–8.
- Karlberg M, McGarvie L, Magnusson M, Aw ST, Halmagyi GM. The effects of galvanic stimulation on the human vestibulo-ocular reflex. *Neuroreport* 2000; 11: 3897–901.
- Karlberg M, Aw ST, Halmagyi GM, Black RA. Vibration-induced shift of the subjective visual horizontal: a sign of unilateral vestibular deficit. *Arch Otolaryngol Head Neck Surg* 2002; 128: 21–7.
- Lackner JR, Levine MS. Changes in apparent body orientation and sensory localization induced by vibration of postural muscles: vibratory myesthetic illusions. *Aviat Space Environ Med* 1979; 50: 346–54.
- Mayoux-Benhamou MA, Revel M, Vallee C. Selective electromyography of dorsal neck muscles in humans. *Exp Brain Res* 1997; 113: 353–60.
- Murofushi T, Halmagyi GM, Yavor RA, Colebatch JG. Absent vestibular evoked myogenic potentials in vestibular neuro-labyrinthitis. An indicator of inferior vestibular nerve involvement? *Arch Otolaryngol Head Neck Surg* 1996; 122: 845–8.
- Popov KE, Lekhel H, Faldon M, Bronstein AM, Gresty MA. Visual and oculomotor responses induced by neck vibration in normal subjects and labyrinthine-defective patients. *Exp Brain Res* 1999; 128: 343–52.
- Robinson DA. A method of measuring eye movement using a scleral search coil in a magnetic field. *IEEE Trans Biomed Eng* 1963; 10: 137–45.
- Robles L, Ruggero MA. Mechanics of the mammalian cochlea. *Physiol Rev* 2001; 81: 1305–52.
- Roll JP, Vedel JP, Ribot E. Alteration of proprioceptive messages induced by tendon vibration in man: a microneurographic study. *Exp Brain Res* 1989; 76: 213–22.
- Sohmer H, Freeman S, Geal-Dor M, Adelman C, Savion I. Bone conduction experiments in humans—a fluid pathway from bone to ear. *Hear Res* 2000; 146: 81–8.

Strupp M, Arbusow V, Dieterich M, Sautier W, Brandt T. Perceptual and oculomotor effects of neck muscle vibration in vestibular neuritis. Ipsilateral somatosensory substitution of vestibular function. *Brain* 1998; 121: 677–85.

Suzuki J, Cohen B, Bender MB. Compensatory eye movements induced by vertical semicircular canal stimulation. *Exp Neurol* 1964; 9: 137–60.

Wit HP, Bleeker JD, Mulder HH. Responses of pigeon vestibular nerve fibers to sound and vibration with audiofrequencies. *J Acoust Soc Am* 1984; 75: 202–8.

Yagi T, Ohyama Y. Three-dimensional analysis of nystagmus induced by neck vibration. *Acta Otolaryngol (Stockh)* 1996; 116: 167–9.

Young ED, Fernandez C, Goldberg JM. Responses of squirrel monkey vestibular neurons to audio-frequency sound and head vibration. *Acta Otolaryngol (Stockh)* 1977; 84: 352–60.

Received June 18, 2002. Revised October 10, 2002.

Second revision November 11, 2002. Accepted November 12, 2002